

Topography-Guided Surface Ablation for Forme Fruste Keratoconus

Tobias Koller, MD,¹ Hans Peter Iseli, MD,¹ Christof Donitzky, Dipl Ing,² Nikolaos Papadopoulos, MD,³ Theo Seiler, MD, PhD¹

Purpose: To evaluate the efficacy of customized surface ablation in cases of forme fruste keratoconus.

Design: Prospective noncomparative case series.

Participants: Eleven eyes of 8 contact lens-intolerant patients with forme fruste keratoconus treated at the Institute of Refractive and Ophthalmic Surgery and the University Eye Clinic Zurich.

Intervention: Topography-guided customized surface ablation by means of a scanning spot excimer laser.

Main Outcome Measures: Visual acuity, refraction, quality of vision (ghosting), corneal topography including the Zernike parameter Z3.

Results: Statistically significant reduction of manifest refractive error, corneal irregularity, and ghosting. The spherical equivalent was reduced by -2.8 ± 0.62 diopters (D) ($P = 0.0007$), the cylinder by 1.34 ± 0.18 D ($P = 0.015$), Z3 was reduced by 41% ($P < 0.001$), and all patients had less ghosting compared to their preoperative status. No eye lost ≥ 1 lines in best spectacle-corrected visual acuity; however, 7 of 11 eyes gained ≥ 1 line.

Conclusion: Topography-guided surface ablation is a promising option to rehabilitate vision in contact lens-intolerant patients with forme fruste keratoconus. *Ophthalmology* 2006;113:2198-2202 © 2006 by the American Academy of Ophthalmology.

Until recently, penetrating keratoplasty (PK) has been the preferred mode of surgical treatment of keratoconus or other forms of keratectasia. New surgical techniques other than PK have been reported with variable success such as LASIK,^{1,2} surface ablation,³⁻⁵ intrastromal rings,⁶⁻⁸ intraocular lenses,⁹ keratotomies,¹⁰ and lamellar keratoplasty.^{11,12} Moreover, crosslinking of the cornea was introduced as a conservative approach to stop progression of the keratectasia process and to transfer the progressive keratoconus into a forme fruste keratoconus cornea.¹³

The forme fruste of a keratoconus is an abortive form of keratoconus and is considered a contraindication for LASIK because LASIK may trigger the halted progression of keratectasia.¹⁴⁻¹⁷ In contrast, surface ablation is much less invasive regarding the biomechanical stability of the cornea and early surface ablation trials documented reasonably good refractive results in cases^{4,5} of keratoconus. At that time, however, customized ablation patterns were not available and, therefore, the visual results limited.

In this pilot study, we report the clinical results of customized topography-guided surface ablation in patients with forme fruste keratoconus.

Materials and Methods

Study Group

Eight patients asking for laser correction in the Institut für Refraktive und Ophthalmochirurgie (IROC) and at the University Hospital Zurich were enrolled in this pilot study. The age of the patients ranged from 28-54 years (average, 40.3 ± 10 years). The refractive and demographic data are listed in Table 1. In 4 patients, a forme fruste keratoconus was diagnosed in both eyes and in 4 patients only 1 eye was affected. One patient had previously had LASIK in the other eye and developed an iatrogenic keratectasia in this eye. All patients have had hard contact lenses for years but could not tolerate them anymore and had not used them for ≥ 6 months before surgery. After a complete ophthalmic examination and a thorough discussion of the risks and benefits of the surgery, patients gave their written consent. Exclusion criteria were any pathology of the eyes besides stable keratectasia, age < 25 years, maximal K-readings ≥ 49 diopters, minimal corneal thickness $< 500 \mu\text{m}$, and predicted residual stromal thickness of $< 450 \mu\text{m}$. The study protocol was approved by the review board of the IROC.

Definition of Forme Fruste Keratoconus

Forme fruste keratoconus is considered an abortive form of keratoconus where the progression process of the keratectasia has stopped at a certain point probably owing to a regained biomechanical strength of the cornea. The term was coined by Amsler based on ophthalmometry readings.¹⁴ Today's diagnostic criteria include virtually all keratoconus signs such as asymmetry of astigmatism in corneal topography of ≥ 1.5 diopters, hemimerid-

Originally received: January 11, 2005.

Accepted: June 20, 2006.

Manuscript no. 2005-29.

¹ Institut für Refraktive und Ophthalmochirurgie, Zurich, Switzerland.

² Wavelight Laser Technologie AG, Erlangen, Germany.

³ Aristotle University of Thessaloniki, Thessaloniki, Greece.

Presented in part at: American Academy of Ophthalmology Annual Meeting, November 2003, Anaheim, California.

Dr Seiler is a scientific consultant to and C. Donitzky is an employee of Wavelight Laser Technologie. Drs Koller, Iseli, and Papadopoulos have no financial interest in this matter.

Reprint requests to Theo Seiler, MD, PhD, Institut für Refraktive und Ophthalmochirurgie, Zollikerstrasse 164, CH-8088 Zurich, Switzerland.

Table 1. Demographic and Refractive Data of the Study Group

Patient	Eye	Age	Best Spectacle-Corrected Visual Acuity	Refraction	Ghosting	Central Corneal Thickness (μm)
1	Right	42	20/30	-0.5 cyl -1.0/120	++	535
	Left		20/30	+0.75 cyl -1.75/105	++	530
2	Right	28	20/30	+0.5 cyl -3.0/80	++	565
	Left		20/25	+0.75 cyl -5.0/10	++	570
3	Left	50	20/25	-2.75 cyl -5.0/95	++	515
4	Right	54	20/60	-6.0 cyl -1.0/50	++	560
5	Left	54	20/80	+2.25 cyl -2.75/90	++	500
6	Right	38	20/16	-4.5 cyl -1.25/87	+	555
7	Right	53	20/30	-5.0 cyl -0.75/82	++	535
	Left		20/20	-4.5 cyl -1.5/92	++	540
8	Right	34	20/16	-1.5 cyl -0.75/75	+	505

cyl = cylinder.

ians oblique > 20 degrees, inferior steepening, Fleischer's iron line, and central subepithelial opacities. However, the authors have never seen Vogt's posterior keratoconus striae in formes frustes of keratoconus. The differentiation of forme fruste from progressive keratoconus is not easy; in many cases, it may be discerned only by history and age of the patient. The following arguments support the diagnosis of forme fruste of keratoconus: (1) no manifest refractive change for years (appropriate is a time span of 3–5 years); (2) annual corneal topography reveals no change within 3 subsequent measurements; and (3) patient age ≥ 40 with a stable refraction makes a forme fruste more likely than a progressive keratoconus; in a 25-year-old patient, it is hard to differentiate between forme fruste and progressive keratoconus. In the 11 eyes of this study group, the corneal topographies were unchanged for ≥ 2 years and the refraction had remained stable for ≥ 4 years.

Clinical Findings

The complete preoperative ophthalmic examination consisted of autorefractometry and autokeratometry (Humphrey Model 599; Zeiss, Jena, Germany), corneal topography (Keratograph C [Oculus, Wetzlar, Germany] equipped with Topolyzer software [Wavelight, Erlangen, Germany]), manifest refraction using the fogging technique, unaided visual acuity (UVA) and best spectacle-corrected visual acuity (BSCVA), glare and low-contrast visual acuity (Humphrey Model 599, Zeiss), wavefront analysis (Wavefront Analyzer, Wavelight), applanation tonometry, central ultrasound pachymetry (SP-2000, Tomey, Nagoya, Japan), and slit-lamp inspection of the anterior and posterior segments of the eyes.

The ghost images recognized by the patients with best spectacle correction were classified in 3 stages: 0, no ghost images visible under any lightning condition; +, ghost images visible only under dim lightning conditions (5 cd/m^2); and ++, ghost images visible under daylight conditions (100 cd/m^2).

The patients were seen on postoperative days 1 and 4, and at 1, 3, 6, and 12 months after surgery. On postoperative days 1 and 4, we determined UVA and a slit-lamp inspection was performed. At the following appointments, the examination was identical to preoperative examinations.

Surgery

All operations were performed as surface ablation procedures either as photorefractive keratectomy (PRK) or laser epithelial keratomileusis (LASEK) by 1 surgeon (TS). The debridement of the epithelium during the PRK was performed with a blunted

hockey knife within a circular area of 9 mm in diameter. In LASEK, the epithelium was slid and folded over the limbus after the application of ethanol 20% for 20 seconds. The laser treatment was performed by means of the Eye-Q excimer laser with T-CAT software (Wavelight). This device works at a repetition rate of 400 Hz and produces a spot size of 0.68 mm with a truncated Gaussian energy profile. Eye tracking is accomplished with a latency of 6 milliseconds. The ablation was centered on the center of the entrance pupil in all cases and the diameter of the treated optical zone was 6 or 6.5 mm surrounded by a transition zone of 1 mm.

After laser application, in LASEK cases the epithelium was repositioned and the patient was served with a bandage lens that was soaked with preservative-free ofloxacin 0.3% eye drops for 20 minutes (Floxal SDU, Bausch & Lomb, Steinhausen, Switzerland). In PRK cases, ofloxacin ointment was used and in addition also a bandage lens. The bandage lenses were removed as soon as the epithelium healed. The surgery in other eye was done ≥ 1 month later. The postoperative medication consisted of fluorometholone 0.1% (Allergan, Lachen, Switzerland) 3 times a day for 1 month and tapered over the following 2 months.

Topography-Guided Ablation

The Topolyzer-software (Wavelight) uses ≤ 8 corneal topographies (Fig 1A) obtained in the automatic mode, which means that the adjustment of the z distance is ≥ 50 microns and in x - y direction ≥ 25 microns. This guarantees a reproducibility of the calculated elevation map of better than ± 5 microns. Corneal topographies were only accepted if measurement data were available within $\leq 90\%$ of the circular area around the pupil center with a diameter of 6.5 mm. The best fit-conoid with an asphericity factor Q is then calculated. The difference elevation map (actual elevation minus best fit-conoid) is approximated with Zernike polynomials (Fig 1B) and from this Zernike fit an ablation pattern is derived (Fig 1C). The software also asks for a target Q factor and in this study a target Q factor of -0.45 was selected.¹⁸ As a last step, it has to be decided whether the tilt (first-order Zernike polynomials) will be included in the ablation pattern or not. In this study, the tilt was neglected in the ablation patterns. The proposed ablation pattern is then transferred to the laser and shot lists are calculated.

Topographical Analysis

Preoperatively and postoperatively, the difference elevation map (actual elevation map minus best fit-conoid) was approximated

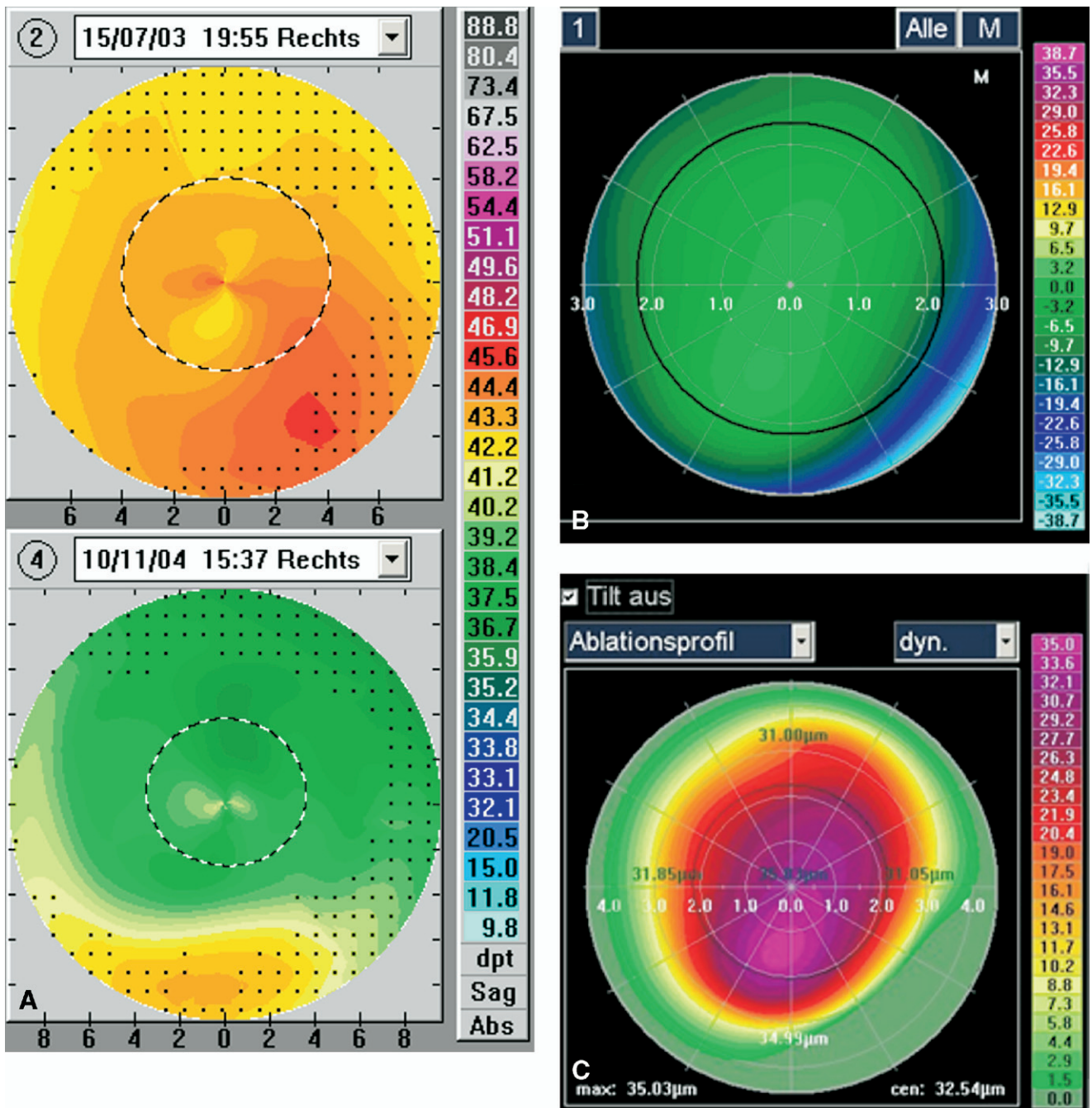


Figure 1. Topography-guided ablation. **A**, Preoperative and 12 months' postoperative corneal topography. Up to 8 corneal topographies are preoperatively averaged and serve as a basis for the calculation of the elevation map. **B**, Difference elevation map. The best fit—conoid is subtracted from the elevation map yielding the difference elevation map, which is approximated by Zernike polynomials. **C**, Ablation pattern. After selecting the target asphericity ($Q = -0.45$) and the spherocylindrical refractive error to be corrected, the ablation pattern is calculated. Abs = absolute scale; cen = central ablation depth; dpt = diopters; sag = sagittal.

within a circular area with a diameter of 6 mm by means of Zernike polynomials to find a parameter for the quality of the correction. Third-order Zernike coefficients are of special interest because coma usually is enhanced in the corneal topography of keratoconus corneas.¹⁹ Following a proposal of Schwiegerling,²⁰ we adapted the parameter Z3 to the videokeratoscope used in this study by means of $Z3 = ((a_{3, \pm 1} - 0.000170)^2 + (a_{3, \pm 3} - 0.000098)^2)^{1/2}$. This parameter was calculated preoper-

atively and compared with the postoperative value at the last follow-up.

Statistical Analysis

The comparison of preoperative and postoperative refractive data was performed by means of the 2-tailed *t*-test, preoperative and postoperative Z3 values were tested for significant reduction by

Table 2. Postoperative Data

Patient	Eye	BSCVA _{pre}	BSCVA _{post}	Refraction _{post}	Ghosting	Follow-up (mos)
1	Right	20/30	20/25	Plano	+	12
	Left	20/30	20/30	Plano	+	18
2	Right	20/30	20/20	+0.5 cyl -2.0/160	0	9
	Left	20/25	20/20	+1.0 cyl -2.5/150	+	10
3	Left	20/25	20/25	-1.25 sph	0	9
4	Right	20/60	20/40	+0.25 cyl -0.75/45	0	12
5	Left	20/80	20/30	+1.5 cyl -1.5/100	0	18
6	Right	20/16	20/12	+0.25 cyl -0.5/90	0	18
7	Right	20/30	20/25	+0.25 cyl -1.0/97	0	24
	Left	20/20	20/20	+0.25 cyl -0.75/116	0	25
8	Right	20/16	20/16	Plano	0	12

cyl = cylinder; BSCVA_{pre/post} = best spectacle-corrected visual acuity preoperatively or postoperatively; sph = sphere.

means of the Wilcoxon matched pairs signed rank test, and for the correlation of preoperative Z3 with the reduction of Z3, we determined the Spearman rank correlation coefficient. Statistical significance was accepted if $P < 0.05$.

Results

All surgeries were uneventful and the bandage lens could be removed on postoperative day 4. None of the patients demonstrated more than trace corneal haze at any time after surgery.

The refractive and visual data at the last follow-up are listed in Table 2. None of the eyes lost any line in BSCVA; however, 7 eyes (63%) gained ≥ 1 line. The refractive error was significantly reduced, spherical equivalent by -2.8 ± 0.62 diopters ($P = 0.0007$) and cylinder by 1.34 ± 0.18 diopters ($P = 0.015$). Ghosting was reduced in all eyes indicating improvement of the performance of the optics of the eyes treated.

The preoperative average of Z3 was 0.001702 ± 0.001024 (range, 0.000423–0.002838); the postoperative average was reduced to 0.001025 ± 0.000596 (range, 0.000419–0.001735). All corneas showed a reduction of the parameter Z3 and the Wilcoxon matched pairs signed rank test revealed this reduction to be highly statistically significant ($P < 0.001$). The Spearman rank correlation coefficient between the reduction of Z3 and the preoperative Z3 values is 0.952, indicating a statistically significant correlation ($P < 0.01$); the higher the initial Z3-value was, the more it was reduced.

Discussion

Two major aspects must be considered regarding any surgical approach of keratectasia disorders of the cornea: (1) visual rehabilitation and (2) weakening of the already reduced biomechanical strength of the cornea.

In this study, we did not address the second point because we relied on earlier reports on a stable cornea in keratoconus after PRK^{3,4}; we also speculated that a residual stromal thickness of 450 microns might be enough to support the biomechanical stability of the cornea even in formes frustes of keratoconus. Based on the experimental data reported,²¹ the biomechanics of the keratoconus cornea is less than a factor of 2 weaker compared to the normal

cornea and because the normal cornea tolerates a residual central thickness of 250 microns, we considered 450 microns sufficient as a lower limit for residual corneal thickness. In addition, by excluding severe cases by means of a maximal K-reading of 49 diopters, we thought to increase the safety margin. We deem it essential to emphasize that these guidelines are speculative and generally accepted limits of forme fruste keratoconus corneas' residual thicknesses and K-readings for a safe ablation are not yet established. In further studies, the minimal corneal thickness should be determined by means of pachymetry maps of the cornea (e.g., using the Orbscan or the Pentacam) rather than by ultrasound pachymetry because of the limited spatial resolution of the ultrasound probe tip. Although in 9 of 11 eyes the follow-up is ≥ 1 year and corneal topography stable within ≥ 6 months, we certainly have to monitor corneal topography, in detail Z3, carefully for up to 5 years to be sure that the photorefractive keratectomy has not induced keratoconus progression in these corneas that were documented to be preoperatively stable for years.

The main topic of this study is the visual rehabilitation of such eyes by means of customized topography-guided surface ablation. Patients with irregular astigmatism owing to forme fruste keratoconus who are contact lens intolerant have no other option today to obtain good visual acuity, because spherocylindrical spectacle correction cannot compensate for the irregular component and penetrating keratoplasty is not yet indicated because visual acuity is not reduced enough. Nine of 11 eyes in this study had a preoperative BSCVA of $\geq 20/40$, and therefore, PK was not yet indicated. However, all patients experienced of ghosting and a reduced quality of vision when using spectacle correction.

It was not the primary goal of this study to improve UVA, but to improve the optical quality of the cornea. Nevertheless, UVA improved in all eyes, mainly owing to the correction of the spherocylindrical refractive error, although BSCVA also improved in 7 of the 11 eyes and no eye suffered a visual loss. All patients reported remarkable reduction of ghost images. Therefore, the primary concern of the approach presented—improvement of the optical performance of the eyes—was achieved.

Numerous attempts have been undertaken to describe the

optical quality of keratoconus corneas including ophthalmometry,¹⁴ corneal topography,^{15,22-24} and aberrometry.²⁵ In this investigation, we chose the Zernike approximation of the elevation deviation from the best fit-conoid. Earlier reports pointed out that the third-order terms are good descriptors of the optical inhomogeneity of corneal optics in keratoconus eyes¹⁹ and especially the parameter Z3 introduced by Schwiegerling and Greivenkamp²⁰ is helpful to detect keratoconus by means of corneal topography. In this study group, the Z3 was significantly reduced by 41% because of the laser treatment, indicating an improvement in the optical performance of the eyes treated. Another important fact regarding the efficiency of the treatment proposed is that the higher the preoperative Z3 the higher the reduction of Z3 was, which means that those eyes most needing the optical improvement received the best reduction of Z3. The fact that even in the small group size of 11 these parameters were statistically significant underlines the clinical significance of the results.

The irregularity of the keratoconus cornea requires a customized approach to transform the corneal shape into toric conoid, either topography or wavefront guided. At first glance, wavefront-guided ablation seems to be the more universal technique because it also includes lenticular optical errors, errors arising from misalignments of cornea and lens, and optical errors of the posterior cornea. However, wavefront analysis frequently does not yield reliable results in highly aberrant eyes,²⁶ which, in our experience, also occurs in keratoconus eyes. Additionally, with regard to further surgery (e.g., for cataracts), photoablative treatment of the cornea must not create new optical problems and should be based only on corneal information. Finally, the locus generis of keratoconus is the cornea and should, therefore, be corrected there.

The results presented herein may have impact on the future management of keratoconus. Recently, it has been shown that the continuous weakening of the biomechanical strength in keratectasia possibly can be stopped by collagen crosslinking¹³ and the progression to a late state where only PK can help to restore vision may be avoided in the future. In essence, by means of collagen crosslinking it may be possible to transfer progressive keratoconus into a forme fruste keratoconus. Such artificially induced formes frustes of keratoconus may be optically homogenized by a customized ablation similar to the cases presented herein.

In summary, this pilot study shows that topography-guided ablation can be an appropriate approach to improve the optical performance of eyes suffering from forme fruste keratoconus. Larger series and longer follow-up are necessary to determine contraindications and limitations of this technique.

References

- Schmitt-Bernard CF, Lesage C, Arnaud B. Keratectasia induced by laser in situ keratomileusis in keratoconus. *J Refract Surg* 2000;16:368-70.
- Buzard KA, Tuengler A, Febraro JL. Treatment of mild to moderate keratoconus with laser in situ keratomileusis. *J Cataract Refract Surg* 1999;25:1600-9.
- Kasparova EA, Kasparov AA. Six-year experience with excimer laser surgery for primary keratoconus in Russia. *J Refract Surg* 2003;19(suppl):250-4.
- Mortensen J, Carlsson K, Ohrstrom A. Excimer laser surgery for keratoconus. *J Cataract Refract Surg* 1998;24:893-8.
- Cochener B, Le Floch G, Volant A, Colin J. Le laser Excimer peut-il tenir une place dans le traitement du keratocone? [Could the laser excimer have a place in the treatment of keratoconus?]. *J Fr Ophtalmol* 1997;20:758-66.
- Colin J, Cochener B, Savary G, Malet F. Correcting keratoconus with intracorneal rings. *J Cataract Refract Surg* 2000;26:1117-22.
- Siganos D, Ferrara P, Chatzinikolas K, et al. Ferrara intrastromal corneal rings for correction of keratoconus. *J Cataract Refract Surg* 2002;28:1947-51.
- Alio JL, Artola A, Ruiz-Moreno JM, et al. Changes in keratoconic corneas after intracorneal ring segment explantation and reimplantation. *Ophthalmology* 2004;111:747-51.
- Sauder G, Jonas JB. Treatment of keratoconus by toric foldable intraocular lenses. *Eur J Ophthalmol* 2003;13:577-9.
- Bowman CB, Thompson KP, Stulting RD. Refractive keratotomy in keratoconus suspects. *J Refract Surg* 1995;11:202-6.
- Busin M, Zambianchi L, Arffa RC. Microkeratome-assisted lamellar keratoplasty for the surgical treatment of keratoconus. *Ophthalmology* 2005;112:987-97.
- Watson SL, Ramsay A, Dart JK, et al. Comparison of deep lamellar keratoplasty and penetrating keratoplasty in patients with keratoconus. *Ophthalmology* 2004;111:1676-82.
- Wollensak G, Spoerl E, Seiler T. Riboflavin/ultraviolet-A-induced collagen crosslinking for the treatment of keratoconus. *Am J Ophthalmol* 2003;135:620-7.
- Amsler M. The "forme fruste" of keratoconus [in German]. *Wien Klin Wochenschr* 1961;8:842-3.
- Levy D, Hutchings H, Rouland JF, et al. Videokeratographic anomalies in familial keratoconus. *Ophthalmology* 2004;111:867-74.
- Seiler T, Quirke AW. Iatrogenic keratectasia after LASIK in a case of forme fruste keratoconus. *J Cataract Refract Surg* 1998;24:1007-9.
- Lafond G, Bazin R, Lajoie C. Bilateral severe keratoconus after laser in situ keratomileusis in a patient with forme fruste keratoconus. *J Cataract Refract Surg* 2001;27:1115-8.
- Manns F, Ho A, Parel JM, Culbertson W. Ablation profiles for wavefront-guided correction of myopia and primary spherical aberration. *J Cataract Refract Surg* 2002;28:766-74.
- Schwiegerling J. Cone dimensions in keratoconus using Zernike polynomials. *Optom Vis Sci* 1997;74:963-9.
- Schwiegerling J, Greivenkamp JE. Keratoconus detection based on videokeratographic height data. *Optom Vis Sci* 1996;73:721-8.
- Andreassen TT, Simonsen AH, Oxlund H. Biomechanical properties of keratoconus and normal corneas. *Exp Eye Res* 1980;31:435-41.
- Maguire LJ, Bourne WM. Corneal topography of early keratoconus. *Am J Ophthalmol* 1989;108:107-12.
- Rabinowitz YS, McDonnell PJ. Computer-assisted corneal topography in keratoconus. *Refract Corneal Surg* 1989;5:400-8.
- Wilson SE, Klyce SD. Quantitative descriptors of corneal topography: a clinical study. *Arch Ophthalmol* 1991;109:349-53.
- Maeda N, Fujikado T, Kuroda T, et al. Wavefront aberrations measured with Hartmann-Shack sensor in patients with keratoconus. *Ophthalmology* 2002;109:1996-2003.
- Wang L, Wang N, Koch DD. Evaluation of refractive error measurements of the WaveScan Wavefront system and the Tracey Wavefront aberrometer. *J Cataract Refract Surg* 2003;29:970-9.